

Study of Diagnostic Efficacy of the Fine Needle Aspiration Cytology of Lymphadenopathy as Compared to Open Biopsy for Histopathological Examination

Sravani P.*, K. Suresh**, Florence Nightingale**

*Department of Pathology, SVS Medical College, Mahabubnagar, Telangana, India. **Department of Pathology, Narayana Medical College, Nellore, Andhra Pradesh.

Abstract

Background: Lymphadenopathy is an abnormal increase in size and/ or altered consistency of lymph nodes. It is a very common clinical manifestation of regional or systemic disease caused by the invasion or propagation of either inflammatory cells or neoplastic cells into the node and serves as an excellent clue to the underlying disease. **Objectives:** The study was undertaken to evaluate the diagnostic efficacy of the fine needle aspiration cytology of lymphadenopathy as compared to open biopsy for histopathological examination, to study the frequency of various neoplastic versus non-neoplastic lesions, their distribution in different age groups and to study the different cytomorphological patterns associated with various lymphadenopathies. **Methods:** A prospective study was conducted in 400 patients with lymphadenopathy referred to the Department of pathology, S.V.S Medical college & Hospital, Mahabubnagar. FNA diagnosis was subsequently correlated and compared with the biopsy diagnosis in the available cases. **Results:** Out of 400 patients of FNAC for lymphadenopathy excisional biopsy was available in only 85 cases. Non neoplastic & neoplastic lesions were seen in 308 cases & 64 cases respectively. 28 smears were non diagnostic. Tuberculous lymphadenitis was the most common lesion in 45.75% of the cases. The overall diagnostic accuracy of FNAC in the present study was 89.41.% with accuracy of 87.19 % for tuberculous lymphadenitis and 100.00% for metastatic carcinoma. Cervical group of lymph nodes were the most commonly affected group of lymph nodes 59.75%. Epithelioid granulomas with necrosis was the predominant microscopic pattern seen in 55.19% cases Overall AFB positivity was seen in 31.14% cases & predominantly seen in necrosis alone pattern(79%), In our study sensitivity, specificity, Positive and negative predictive values of FNAC in lymphadenopathy were 100 %, 96.97%, 90.48% and 100 % respectively. **Conclusion:** FNAC is a simple, rapid, cost effective diagnostic tool for patients having significant lymphadenopathy. The metastatic carcinomas, and tuberculous lymphadenopathy can be diagnosed by FNAC with a high degree of accuracy. If FNAC is positive surgeon can proceed to treat the patient without excisional biopsy of the enlarged lymph nodes & most of the diseases are medically curable with limited role for surgery in non-neoplastic lesions. Lack of tissue architecture on FNAC can be overcome by subjecting samples to flow cytometry, T-cell, B-cell markers and immunocytochemistry analysis.

Keywords: Lymphadenopathy; Diagnostic Efficacy; Fine Needle Aspiration Cytology and Histopathological Examination.

Introduction

Lymphadenopathy is an abnormal increase in size and/ or altered consistency of lymph nodes. It is a

clinical manifestation of regional or systemic disease and serves as an excellent clue to the underlying disease [1].

The use of fine needle aspiration cytology (FNAC) in the investigation of lymphadenopathy has become an acceptable and widely practiced minimally invasive technique, which is safe, simple, rapid and relatively pain-free.

FNAC is highly cost effective and accurate as a first

Corresponding Author: K. Suresh, Associate Professor, Department of Pathology, Narayana Medical College, Nellore-524003, Andhra Pradesh.

E-mail: suresh_harithasa@yahoo.com

(Received on 04.03.2017, Accepted on 17.03.2017)

line investigative technique with differential diagnosis including reactive hyperplasia/inflammatory conditions, granulomatous disorders and malignancy, stratifying cases requiring further investigations, surgical intervention or clinical follow-up [1].

In the past the assessment of the lymphadenopathy was made indirectly from the clinicopathological parameters or biopsy, but with the resurgence of the FNA as diagnostic tool in the evaluation of lymphadenopathy, procedure of biopsy is avoided in most of the cases as FNA is fairly accurate in the diagnoses of Lymphadenopathy [2]. The value of FNAC, besides making a diagnosis, also lies in early direction of appropriate investigations.

Aspirates from lymph nodes are usually very cellular and their interpretation varies from clear diagnosis to a firm request for histopathology. However, limitations and pitfalls of the procedure should be recognized. The knowledge of the pattern of lymphadenopathy in a given geographical region is essential for making a confident diagnosis or suspecting a disease [3].

Tuberculosis is the commonest cause of lymphadenopathy in developing countries like India and should be considered in every case of granulomatous lymphadenopathy unless proved otherwise [3].

The cytomorphological features obtained in needle aspiration, frequently correlate very well with histologic appearance of the same lesion and in some situations has qualities of a micro-biopsy. In conjunction with radiologic studies, it provides ease in following patients with known malignancy and ready identification of metastasis or recurrence [2].

The diagnostic accuracy can be further increased if cytological findings are correlated with clinical findings and other simple investigations such as X-Rays, peripheral smear, ESR and Mantoux test. The appropriate use of FNA may obviate the need for an open biopsy.

Use of aspiration cytology is accepted as a primary method of diagnosis in reactive, infective and metastatic lymphadenopathy and in combination with immunological evaluation has distinctly improved diagnostic accuracy in cases of lymphoma [4]. But, predominantly, cytomorphology alone decides the nature of lymphadenopathy.

FNA cytology remains the first line investigation in cases of lymphadenopathy. Besides initial diagnoses of lymphoma, it helps in detection of residual disease, recurrence and progression of low grade to high grade lymphoma and helps in the staging of disease. Various

special ancillary techniques are now being performed on lymph node aspirates to diagnose lymphoma versus other malignancies and to decide the functional character of lymphoma and their clonal nature [5].

FNAC has become the primary investigative procedure for mass lesions in HIV-positive patients, particularly in the assessment of lymphadenopathy. Lymphadenopathy is one of the earliest manifestations of HIV. This may be due to the presence and effects of HIV [6]. Lymphadenopathy may also be a manifestation of opportunistic infections, lymphoid malignancy developing in an immunodeficient individual.

The procedure is rapid, easily performed and in many cases obviates excision while guiding subsequent therapy or observation [7].

FNA is a useful tool to determine whether the enlarging lymph nodes are related to viral or opportunistic infections, Kaposi sarcoma, high-grade lymphoma, or metastatic carcinoma. Needle aspiration biopsy and flow cytometry of lymph nodes has been proposed as potentially useful in assessing the clinical status of HIV-infected patients.

The use of Fine Needle Aspiration Cytology (FNAC) for the diagnosis of metastatic malignancies in the lymph nodes is a well-established method [8]. Lymphadenopathy may be the first sign of malignancy in a patient. FNAC not only confirms the presence of metastatic disease, but also gives clues regarding the nature and origin of the primary tumour.

In patients with enlarged lymph nodes and previously documented malignancy, FNAC can obviate further surgery performed merely to confirm the presence of metastasis [9]. The false-positive rate of lymph node FNAC for the detection of metastasis is quite low (in the range of 0.9-1.7%). Avoiding false-positive diagnosis is of obvious importance since therapeutic and surgical decisions are often based exclusively on cytology results [8].

It is safe alternative to excision biopsy and recommended as a first line investigation as compared to excision biopsy because it diagnosed 80% of T.B by FNA [10]. Its sensitivity and specificity have been documented by several studies in the past [11]. FNA of lymph nodes has high sensitivity and specificity in the distinction between a benign and malignant lesion.

Accuracy estimates for lymph node FNA vary because of local variations in technique and referral patterns, but most investigators report over 90% accuracy in the diagnosis of metastatic tumor to lymph nodes, and a positive predictive value of almost 100%

[12]. Similarly, the accuracy of a diagnosis of Hodgkin lymphoma is high [13], with a positive predictive value over 90% [14].

The present study is undertaken to evaluate the usefulness of FNAC as a diagnostic tool in cases of lymphadenopathy and study the different cytomorphological patterns associated with various lymphadenopathies in H & E and performing acid fast staining in suspected tuberculous cases.

Materials & Method

The study was conducted in S.V.S Medical college & hospital, Mahabubnagar. 400 patients with significant lymphadenopathy referred to the department of pathology during the time period of 1st August 2009 to 31st July 2011 were included in the study.

Age 1 to 80 years, Enlarged non-tender lymph nodes ≥ 0.5 cm in diameter and patients presenting with superficial or deep lymphnode enlargement were included.

Patients less than 1 year of age and patients where FNAC of the node could not be carried out were excluded.

Thorough general physical examination was carried out. Palpable peripheral lymphnodes were examined noting their size, location, consistency, number, mobility, presence of matting and presence of any local changes like redness, discharge or sinus formation.

In the present study out of 400 cases of FNAC only 90 cases were followed by biopsy.

Procedure

Overlying skin is stretched and the lymph node grasped between the index finger and thumb of left hand; a sterile 22 or 23 gauge needle is fitted to a 5-10 ml syringe and pierced obliquely into the lymph node. Deep seated nodes were aspirated using USG or CT guidance under local anaesthesia. The aspirate is examined for the amount and nature of the aspirated material, and then

several smears are prepared. Smears are immediately fixed in 80% isopropyl alcohol and stained by Haematoxylin and eosin stain. Air-dried smears are also prepared and stained with Ziehl-Neelsen stain for the cases where necrotic material is aspirated or tuberculosis suspected, for the demonstration of acid-fast bacilli. Smears are examined under microscope for the cytological picture.

Interpretation

After studying all the available clinical data, retrieved from the hospital the smears were examined under the microscope. Based on the cellularity the smears were categorized as of high, moderate or low cellularity. Those smears which were haemorrhagic or with scanty cellularity to such an extent that diagnosis could not be offered were labelled as inadequate for opinion.

Results

The present study includes 400 patients with lymphadenopathy referred to Department of pathology, S.V.S medical college & Hospital between August 2009 and July 2011. These cases were taken for Fine Needle Aspiration Cytology (FNAC), but in 28 cases FNAC was inconclusive. Excisional biopsy was available in only 85 cases (21.25%), finally these cases were analysed in detail.

Maximum number of cases 255(63.75%) were between 11-40 years age group and the female to male

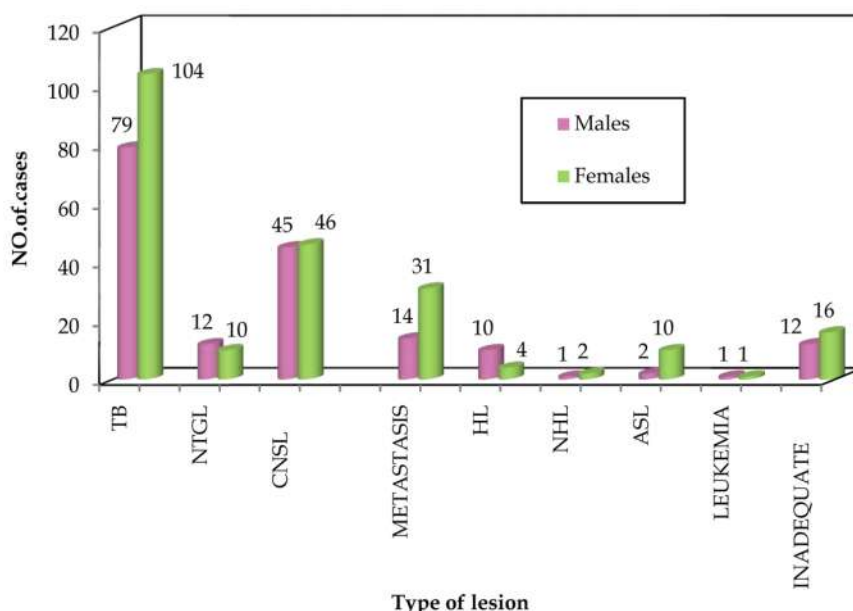


Fig. 1: Showing sex distribution in various lesions

ratio was 1.13:1 (Figure 1).

Out of these 400 cases, 183 cases (45.75%) were confirmed as tuberculous lymphadenitis, 91 cases (22.75%) as chronic non-specific lymphadenitis, 45 cases (11.25%) as secondaries, 22 cases (5.5%) as non tuberculous granulomatous lymphadenitis, 17 cases (3.8%) as lymphomas, 12 cases (3%) as acute suppurative lymphadenitis, 2 cases (0.5%) as leukemic infiltration.

Thus among the lesion of lymph nodes tubercular etiology was the most common. The causes of lymphadenopathy were broadly classified as neoplastic and non-neoplastic lesions.

In lymphnodes, non-neoplastic lesions were more common than neoplastic lesions constituting 77% of total cases. 64 cases (16%) are of neoplastic in nature. Inadequate smears constituting about 7% (28) of the total cases.

Granulomatous lymphadenitis of tuberculous etiology is the most common Cause of lymphadenopathy seen in 183 cases (59.45%) followed by chronic nonspecific lymphadenitis in 91 cases

(29.5%). 7.15% of the cases show non tuberculous granulomatous lymphadenitis & acute suppurative lymphadenitis in 12 cases (3.90%).

Among the neoplastic lesions, metastasis had maximum number of cases 45(70.4%) followed by Hodgkins lymphoma in 14 cases (21.8%) & Non hodgkins lymphoma in 2 cases (3.2%). Leukemic infiltration is seen in only 2 cases (3.2%).

The minimum age of the patient presenting with lymphadenopathy is 14 months & the maximum age being 80 years. The maximum incidence was in the age group of 11 years to 40 years which was in 255 cases (63.75%). Maximum incidence of TB lymphadenitis was between the ages of 11 years to 40 years(138 cases, 34.5%). In secondaries maximum incidence was found between 40 years to 70 years (31 cases, 7.75%). Lymphomas reported were common between 11-30 years (8 cases 2%). The age of the patients reported as ALL & CLL were 10 years & 41 years respectively.

Male to female ratio was found to be 1.13 : 1, there is slight female preponderance in most of the lesions.

Table 1: Sex distribution in various lesions

S. No.	Cytology Diagnosis		Males	Females	Total
1.	Granulomatous lymphadenitis	TB	79	104	183
		NTGL	12	10	22
2.	CNSL		45	46	91
3.	METASTASIS		14	31	45
4.	Lymphoma s	HL	10	4	14
		NHL	1	2	3
5.	ASL		02	10	12
6.	LEUKEMIA		1	1	2
7.	INADEQUATE		12	16	28
	TOTAL		188	212	400

But in metastasis there is male predominance (2.9 : 1) (Table 1).

In all the type of lesions cervical group is the most common group involved in almost 239 cases (59.75%). tuberculous lymphadenopathy most commonly

presented with cervical lymphadenopathy in about 118 cases.(64.48%) Next common mode of presentation is generalized lymphadenopathy seen in 45 cases (%) which is seen mostly in tuberculous lymphadenitis (30 cases) & hodgkins lymphoma (8 cases), followed by submandibular group seen in

Table 2: Showing various sites involved in lymphnode lesions

SITE	TBLN	CNSL	NTGL	ASL	Metastasis	lymphoma		leukemia	inadequate	Total
						HL	NHL			
Cervical	118	58	12	09	25	02	02	00	16	239
Submandibular	22	17	07	02	04	07	01	00	09	69
Axillary	14	08	00	00	10	01	00	00	02	35
Inguinal	02	03	01	00	04	01	00	00	00	11
Generalised	30	03	02	00	00	08	00	02	00	45
Others	00	02	00	02	02	01	00	00	01	08
Total	183	91	22	12	45	17	03	02	28	400

69 cases (%). Axillary group is involved in 35 cases (%) and most of them are metastatic deposits from breast carcinoma (Table 2).

Majority of patients 194 cases (48.5%) presented with lymphnodes of more than 1 cm in size. Size ranging from 2x2 to 6x5 cm. 171 patients presented

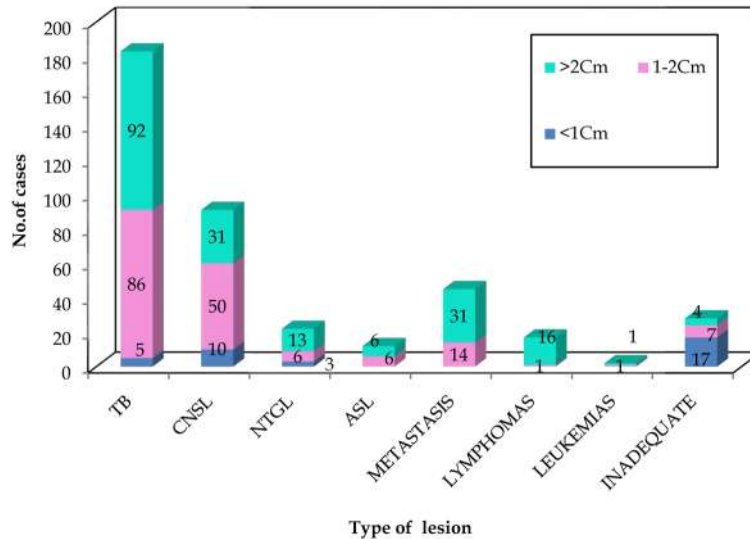


Fig. 2: Showing size of lymphnode lesions

with lymphadenopathy of 1-2Cm in size. Only 35 patients (8.75%) had lymphnodes of less than 1 cm (Figure 2).

patients(20%). The maximum number of nodes were between 1-2 in 296 patients (74%)

Firm in consistency was the most commonest (82%) clinical finding. Matting was present in 80

The cytological diagnosis was correlating with clinical diagnosis in about 81 cases, in tuberculous

Table 3: Correlation of clinical & cytopathological diagnosis

Clinical Diagnosis	Cytology Diagnosis								
	TBLN	CNSL	NCGL	ASL	Metastasis	Lymphoma HL	NHL	Leukemia	Inadequate
TBLN	81	06	07	02	10	14	00	01	07
CNSL	94	77	14	07	02	00	00	00	20
NTGL	01	00	00	00	00	00	00	00	00
ASL	00	02	00	02	00	00	00	00	00
METASTASIS	00	03	00	01	32	00	00	00	00
HL	04	00	01	00	01	00	00	00	01
NHL	00	00	00	00	00	00	02	00	00
LEUKEMIA	00	00	00	00	00	00	00	01	00
OTHERS	01	03	00	00	00	00	01	00	00

lymphadenitis & in 77 cases in case of chronic nonspecific lymphadenitis .In Metastasis the clinical diagnosis was correlating with FNAC diagnosis in 32 cases (Table 3).

Out of 183 cases of tuberculous lymphadenitis AFB positivity is seen in 57 cases (31.14%). AFB positivity was seen predominantly (79%) in necrosis alone pattern, followed by granulomas with necrosis pattern in (14%). AFB Positivity was seen in only 04 cases (07%) in smears showing epitheloid cell granulomas alone.

In the present study epithelioid granulomas with necrosis was the predominant microscopic pattern seen in 101cases (55.19%), followed by granulomas without necrosis in 42 cases (22.95%) and caseous necrosis without granuloma in remaining 40 cases (21.86%).

Among the seconadries to lymphnodes squamous cell carcinoma deposits were common seen in 24 cases (53.34%). Next common diagnosis being ductal cell carcinoma in 8 cases (17.78%) followed by

papillary carcinoma in (8.88%), anaplastic carcinoma 06.68%, adenocarcinoma, nasopharyngeal carcinoma, small cell carcinoma, testicular car carcinoma & malignant melanoma in 2.22% cases.

Table 4: Diagnostic co-relations of FNAC

Cytology Diagnosis	TBLN	CNSL	NTGL	Histopathology METASTASIS	diagnosis LYMPHOMA		LEUKEMIA	Total
					HL	NHL		
TBLN	34	00	01	00	00	00	00	35
CNSL	04	18	00	00	00	00	00	22
NTGL	01	01	05	00	00	00	00	07
METASTASIS	00	02	00	07	00	00	00	09
HL	00	00	00	00	08	00	00	08
NHL	00	00	00	00	00	02	00	02
LEUKEMIA	00	00	00	00	00	00	02	02
Total	39	21	06	07	08	02	02	85

with histopathology diagnosis. There was only one false positive case reported which was later on reported as non tuberculous granulomatous lymphadenitis by biopsy (Table 4).

The Sensitivity, Specificity, PPV & NPV of FNAC in diagnosing tuberculous lymphadenitis are 87.19%, 97.8%, 97.14% & 90% respectively.

Out of 22 cases of chronic nonspecific lymphadenitis on FNAC 18 cases were confirmed by biopsy as chronic nonspecific lymphadenitis & 4 false positive cases were noted. Sensitivity, Specificity, PPV & NPV being 85.71%, 93.75%, 81.82%, 95.24% respectively.

Correlation Diagnosis

Out of 400 cases of FNAC biopsy was available only in 85 cases & correlation could be done in only these cases. Out of 35 cases of FNAC diagnosis of tuberculous lymphadenitis 34 cases were correlating

FNAC diagnosis of non tuberculous granulomatous lymphadenitis was confirmed with biopsy in 5 cases & false positives seen in 2 cases. Sensitivity, Specificity, PPV & NPV being 83.3%, 97.5%, 71.4%, 98.71% respectively.

9 cases of Metastatic deposits diagnosed on FNAC were followed by biopsy, in which 7 cases were correlating & 2 false positive cases were seen.

The Sensitivity, Specificity, PPV & NPV of FNAC in diagnosing metastatic deposits were 100%, 97.4%, 77.8% & 100% respectively.

No false positives recorded in diagnosing lymphomas & leukemias by FNAC & both the

Table 5: Sensitivity & specificity of FNAC over biopsy in various lesions

Type of lesion	Sensitivity	Specificity	Positive predictive value	Negative predictive value	% of False negatives	% of False positives
TBLN	87.2 %	97.8 %	97.14 %	90 %	12.82 %	2.17 %
CNSL	85.71 %	93.75 %	81.82 %	95.24 %	14.28 %	6.25 %
NTGL	83.3 %	97.5 %	71.4 %	98.71 %	16.67 %	2.53 %
Metastasis	100 %	97.4 %	77.78 %	100 %	00 %	2.56 %
HL	100 %	100 %	100 %	100 %	00%	00%
NHL	100 %	100 %	100 %	100 %	00 %	00 %
Leukemia	100 %	100 %	100 %	100 %	00 %	00 %

Table 6: Showing overall diagnostic efficacy of FNAC :

TEST	HPR (+)	HPR (-)	TOTAL
FNAC +	19	02	21
FNAC -	00	64	64
TOTAL	19	66	85

sensitivity & specificity were 100 %.

The sensitivity of FNAC for diagnosing tuberculosis, chronic non-specific lymphadenitis, malignant secondaries, lymphomas was 87.2%,

85.71% , 100% & 100% respectively.

Comparisio

Comparing FNAC results with histopathologic

diagnoses revealed that 64 cases were diagnosed both by FNAC & Histopathology as benign. In 19 cases malignant lesions were diagnosed the same in histopathology also. In 02 cases benign lesions were overdiagnosed as malignant lesions representing false positives. there were no false negatives in the present study.

FNAC had a sensitivity of 100% and a specificity of 96.97%. Positive and negative predictive values of this method were 90.48% and 100 % respectively. (Table 6).

Discussion

In developing countries like India where tuberculosis is the major problem and facilities for the biopsy are not readily available at the primary health care level, FNAC can be very useful in providing a diagnosis. It also reduces pressure on financial resources necessary for surgical procedures like open biopsy for diagnosis confirmation.

In our study out of 400 patients of lymphadenopathy 308 cases (77%) were of non neoplastic (benign) in nature & 64 cases (16%) were of neoplastic (malignant) in nature. Non diagnostic smears constituting 7% of the total cases. These findings correlate well with the results reported by Ahmed et al who studied 50 cases out of which 37 cases (74%) were benign, 11 cases (22%) were malignant & 4% of the cases were nondiagnostic smears [15]. However, Steel et al reported 59% cases of malignant lesions and 29, 8% cases of benign lesions [8]. This may be attributed to the fact that western countries, where these studies were carried out show predominance of malignant conditions over benign conditions.

In our study bulk of diseases are of tubercular lesions and of reactive nature due to infections, which are uncommon in western countries. In the present series, tuberculosis accounted for 45.75% of cases, 22.75% of cases were diagnosed as chronic non-specific lymphadenitis, 5.5% as non tuberculous granulomatous lymphadenitis, 3% as acute suppurative lymphadenitis. Among the neoplastic lesions, malignant secondaries accounted for 11.25% of cases and Hodgkin's lymphomas in 3.5% of cases while non-Hodgkin's lymphoma comprised 0.75% & leukemias in the remaining 0.05% of the cases. Similar observations were made by Jha B.C. et al., [16] who studied 94 cases, of which tuberculosis was confirmed in 63.8% cases, chronic non-specific lymphadenitis in 5.9%, reactive lymphadenitis in 9.6% & malignant

lesions consist of metastatic deposits & lymphomas in 20.79% of the cases.

The study done by Pradeep Reddy et al showed that lymph nodes measuring more than 1cm in the cervical and axillary region, more than 1.5cm in the inguinal region and at any other site more than 0.5cm are considered significant [17].

In this study there were 35 cases of lymph nodes measuring <1cm in greatest dimension. Of this 33 were in the cervical region, 2 in the axillary region. Out of these 17 cases were inadequate for opinion due to scanty aspirate.

Tuberculous lymphadenitis proved to be the most common diagnosis in our study (45.75%). In India, tuberculous lymphadenitis is one of the most common type of lymphadenopathy encountered in clinical practice in India [2, 5, 6]; whereas it is in sharp contrast to very low frequency of 1.6% in western studies [7].

In our study maximum incidence of TB lymphadenitis was between the ages of 11 years to 40 years (138 cases, 34.5%). with female preponderance, male to female ratio being 1:1.32. Lymph nodes of the neck (64.48%) followed by generalised lymphadenopathy (7.5%) are the most common sites involved. The cervical group of lymph nodes was most commonly involved as was the case in most other series [3,18,19]. This is attributable to the rich lymphatic supply in the neck region [3,4,20].

Tuberculous lymphadenopathy was the most common diagnosis in our study accounting for 45.75% of the total cases with an accuracy of 87.19% on FNAC with histopathological correlation which is comparable to similar studies.

The study done by Gupta K.A has also reported accuracy of 76.78% for tuberculous lymphadenopathy to an histological correlation [21].

In the present study out of 39 patients of tuberculous lymphadenopathy on biopsy 34 cases were reported on FNAC. In 04 cases the diagnosis of chronic non specific lymphadenitis & in 01 case non tuberculous granulomatous lymphadenitis was offered in FNAC.

In our study epithelioid granuloma with necrosis was the predominant cytological pattern seen in 55.19% of cases which is in accordance with study conducted by Das D. K et al, Handa U et al and Gupta A.K et al [5, 21, 22]., The other common cytological pattern observed was epithelioid granuloma without necrosis seen in 22.95% cases and caseous necrosis alone seen in 21.86%. cases.

In doubtful cases Ziehl-Neelsen staining is helpful in demonstrating the presence of acid fast bacilli. In the present study out of 183 cases of tuberculous

lymphadenitis 57 cases (31.14%) were positive for acid fast bacilli on Ziehl-Neelsen staining which helped in giving diagnosis of tuberculous lymphadenopathy.

AFB positivity was seen predominantly in necrosis alone pattern (79%), followed by granulomas with necrosis pattern in 14% of total AFB positive cases. AFB Positivity was seen in only 04 cases (07%) in smears showing epithelioid cell granulomas alone.

Problem arises in definite diagnosis in tuberculous lymphadenitis cases when Langhan's giant cell, and epithelioid cells are not seen in the smear or when smear contains only caseous material or pus. Hence in our study we had 5 false negative reports on FNAC for tuberculous lymphadenopathy being reported as nonspecific chronic lymphadenitis in 4 cases & non tuberculous granulomatous lymphadenitis in 1 case.

There was 1 false positive case reported in the present study this may be because of the presence of epithelioids & giant cells in hodgkins lymphomas well. In the present study cervical group was the most common group affected with tuberculous lymphadenitis constituting 118 out of 183 cases (64.48%).

In the present study, chronic non specific lymphadenitis is the next common cause of lymphadenopathy accounting for 22.75 % of the total 400 cases. chronic non specific lymphadenitis had high number of false positive cases (i.e. 4 cases) in the present study as patients with tuberculous lymphadenopathy, Hodgkin's lymphoma may have similar polymorphous picture on aspirates as chronic non specific lymphadenitis in absence of Langhan's cells / epithelioid clusters and Reed-Sternberg's cells respectively. 18 cases had histopathological confirmation as chronic non specific lymphadenitis.

The present study has accuracy of 85.71% for diagnosing chronic non specific lymphadenitis on FNAC which is comparable with other studies. In the study done by Gupta A. K. (1990) reported accuracy of 76.90% of cases on FNAC [21].

In the present study, non tuberculous granulomatous lymphadenitis is seen in 5.5 % of the total 400 cases, non tuberculous granulomatous lymphadenitis had 2 false positive cases in the present study as non caseating granulomas can be present in patients with tuberculous lymphadenopathy & Hodgkin's lymphoma as well. 07 cases were available for histopathological correlation & 6 cases were confirmed by biopsy. In the present study the diagnostic accuracy of FNAC for non tuberculous granulomatous lymphadenitis in the present study was 83.33%.

In the present study, we had 17 cases of lymphomas out of which 14 were of hodgkins type and 3 were Non-Hodgkin's lymphoma. 08 cases of Hodgkin's lymphoma & 02 cases of Non-Hodgkin's lymphoma were available for histopathological examination. There were no false positive & false negative cases of lymphoma on FNAC. Out of 8 cases of hodgkins lymphoma 6 cases were of mixed cellularity type & 01 case of lymphocyte rich type & another case was of lymphocyte predominant type.

In 03 cases of non hodgkins lymphoma one was reported as burkitts lymphoma with starry sky pattern. In the present study, number of cases of Non-Hodgkin's lymphomas are too small hence accuracy of FNAC cannot be authentically arrived in our study for non hodgkins lymphoma of lymph nodes. The other studies have reported diagnostic accuracy in the range of 80 -90% [23,24].

For Hodgkins lymphoma the diagnostic accuracy in the present study is 100 %. The study done by Das D.K. (1991), reported accuracy of 90.00% [24]. Another study done by Kline T. S. (1978) had reported diagnostic accuracy of only 60.00% for lymphomas [25]. The increased accuracy of FNAC for lymphomas in the present study may be because of the typical clinical presentation and cytopathological features in all lymphoma patients.

In the present study, the overall diagnostic accuracy on cytopathological correlation for metastasis to lymph nodes was 100.00%, as 7 out of 7 cases of metastatic deposits were diagnosed on FNAC.

There were 45 patients of metastatic carcinoma in the present study, of which 24 belonged to squamous cell carcinoma, 08 were of ductal cell carcinoma (breast carcinoma), papillary carcinoma in 04 cases, anaplastic carcinoma in 03 cases, malignant melanoma in 02 cases, adenocarcinoma, nasopharyngeal carcinoma, small cell carcinoma & testicular carcinoma in 01 case each.

Of the 45 cases of metastatic deposits on FNAC, 21(46.67%) cases had known primary. In the study by Osama Gaber et al [26], it was possible to establish primary in 86.7% whereas in the present study it was only 46.67%, this was because of limited resources available in the hospital.

The primary lesions in these 21 cases were as follows. In 10 cases of squamous cell carcinoma deposits 4 patients had lung carcinoma, 2 patients had laryngeal carcinoma and 02 patients had squamous cell carcinoma penis, 1 had cervix carcinoma & 1 patient had breast carcinoma. The key to diagnosis on FNAC is cohesive cell group and common cell borders. The cells are of the large, keratinized and pleomorphic type.

In the present study 14 cases were diagnosed as metastatic squamous cell carcinoma to the cervical lymph nodes on FNAC with unknown primary 45. There were 02 false positive cases of squamous cell carcinoma reported as, chronic non specific lymphadenitis as the needle might have missed the particular area of malignant metastatic cells in the lymph node.

In the present study there were 6 cases of metastatic carcinoma to axillary nodes from mammary origin & all were diagnosed on FNAC as infiltrating ductal carcinoma giving an accuracy of 100%.

In our study for the anaplastic carcinoma secondaries, primary was from esophagus in one case & testes in another case. Toe was the primary site in malignant melanoma secondary deposits. Thyroid was the primary site in papillary carcinoma metastasis to cervical lymphnodes. For the small cell carcinoma metastasis lung was the primary site.

7 out of 7 cases of metastatic deposits were diagnosed on FNAC. There were no false negative results but 02 false positive cases were seen. Thus the Sensitivity, Specificity, PPV & NPV of FNAC in diagnosing metastatic deposits were 100%, 97.4%, 77.8% & 100 % respectively.

The study done by Prasad R. (1993) reported 100.00% accuracy in cases of metastatic carcinoma to lymph nodes [27]. The study done by Narang R. H. reported, 60-89% accuracy for metastatic carcinoma [28].

Our findings also correlate with the above mentioned studies, reporting 100% accuracy for metastatic carcinoma. The age in the present study for metastatic cell carcinoma is between 35 - 65 years, disease more common in females than males by ratio of 2.21:1. The overall diagnostic accuracy in metastatic carcinoma in present study is 100.00% which is same as similar studies of Prasad R et al, Narang R. H et al [28,29]

In the present study there were 2 cases of leukemias. In one case the diagnosis was ALL & in another case the diagnosis was CLL. Both the leukemia patients had generalised lymphadenopathy & the peripheral smear was showing ALL & CLL picture respectively. ALL patient was 10 years old male & CLL patient was 41 years old. Both the cases were confirmed by biopsy also.

In our study FNAC had a sensitivity of 100% and a specificity of 96.97%. Positive and negative predictive values of this method were 90.48% and 100% respectively. This is in comparison with other similar studies [15,30].

Conclusion

Fine needle aspiration cytology was found to be reliable and cheapest method of diagnosis without any significant morbidity and with good patient compliance. FNAC is a reliable diagnostic tool in the patients having significant Lymphadenopathy.

A definite diagnosis by FNAC obviates the need for surgical excision as most of the diseases diagnosed by FNAC itself without the need for biopsy like non-neoplastic lesions are medically curable & with FNAC the lymph node lesions can be categorized in to benign and malignant categories.

FNAC can be deemed as a frontline investigation with further investigations on the basis of FNAC result. However, histopathological examination remains the most dependable diagnostic tool.

Even if a lymph node measures <1cms it is still worthwhile to do an FNAC. In our study even though FNAC from the 48.57% of the cervical lymph nodes measuring < 1cms were inadequate, the other 51.43% cases yielded diagnostic material.

The metastatic carcinomas, especially squamous cell carcinoma and tuberculous lymphadenopathy can be diagnosed by FNAC with a high degree of accuracy. However the differentiating features are not well demarcated in reactive hyperplasia .

In the present study, accuracy was of 87.19% for tuberculous lymphadenitis which had improved because of Zeihl-Neelsen staining for acid fast bacilli. Therefore it must be stressed that when the fine needle aspirate appears purulent or when tuberculosis is clinically suspected, specimen should be stained for acid fast bacilli. It improves diagnostic capability of fine needle aspiration cytology. In a granulomatous lymphadenopathy a careful search for abnormal cells has to be done before wrongly diagnosing tuberculosis.

In the present study, overall diagnostic accuracy was 100.00% for metastatic carcinoma . In cases of metastasis of unknown origin to cervical and axillary lymphadenopathy. FNAC is useful adjunct to diagnostic procedures and can point to primary depending upon the cell type. In the present study FNAC could detect primary in 46.67% cases.

Open biopsy for histological confirmation is gold standard, but it has its limitations because it distorts the surgical planes and may increase risk of induction of tumour spread especially in metastatic upper and middle cervical lymph nodes which are potentially curable with radiotherapy or node dissection. FNAC

is preferable and if it is positive, surgeon can proceed to treat the neck without excisional biopsy of the enlarged lymph nodes.

Early diagnosis of lymphoma by FNA especially Hodgkin's disease, may contribute to cure of the disease. There is significant limitation in the assessment of low grade Non-Hodgkin's lymphoma in cases of substantial non malignant component but FNAC can assess correctly high grade Non Hodgkin's lymphoma.

The most difficult areas in diagnosis of lymph node disease by FNAC is differentiating low grade lymphoma from reactive hyperplasia. Though limitations and pitfalls exist in the diagnosis of lymphoma by FNA, but it still plays a major role in the primary diagnosis & staging and in recurrence of the disease.

Lack of tissue architecture can be overcome on FNAC samples by subjecting them to dual parameter flow cytometry, T-cell, B-cell tumour markers and immunocytochemistry analysis.

Finally we conclude that, FNAC is simple, safe, self reliable, cost effective and less time consuming out patient procedure which can be used as an initial diagnostic tool for lymphadenopathies but the limitation of the procedure should be kept in mind. If FNAC is negative it does not rule out the disease and should be followed by open biopsy for histopathological confirmation.

References

- Bhuiyan MAH, Fakir MAY, Hossain AT, Huq AZ, Gupta S: Role of Fine needle aspiration cytology in the diagnosis of cervical lymphadenopathy. *Bangladesh Journal of Otorhinolaryngology* 2008; 14(2): 63-65.
- Chu E, Hoyer R: The clinician and the cytopathologist evaluate fine needle aspiration cytology. *Acta cytologica* 1972; 17(5):413-417.
- Khajuria R, Goswami K, Singh K, Dubey V: Pattern of lymphadenopathy on fine needle aspiration cytology in Jammu. 2006.
- Oertel J, Oertel B, Kastner M, Lobeck H, Huhn D: The value of immunocytochemical staining of lymph node aspirates in diagnostic cytology. *British journal of haematology* 1988; 70(3):307-316.
- Das DK: Value and limitations of fine needle aspiration cytology in diagnosis and classification of lymphomas: A review. *Diagnostic cytopathology* 1999; 21(4):240-249.
- Vanisri H, Nandini N, Sunila R: Fine-needle aspiration cytology findings in human immunodeficiency virus lymphadenopathy. *Indian Journal of Pathology and Microbiology* 2008; 51(4):481.
- Shobhana A, Guha S, Mitra K, Dasgupta A, Neogi D, Hazra S: People living with HIV infection/AIDS-A study on lymph node FNAC and CD4 count. *Indian journal of medical microbiology* 2002; 20(2):99.
- Steel BL, Schwartz MR, Ramzy I: Fine needle aspiration biopsy in the diagnosis of lymphadenopathy in 1,103 patients. Role, limitations and analysis of diagnostic pitfalls. *Acta cytologica* 1994; 39(1):76-81.
- Üstün M, Risberg B, Davidson B, Berner A: Cystic change in metastatic lymph nodes: A common diagnostic pitfall in fine needle aspiration cytology. *Diagnostic cytopathology* 2002; 27(6):387-392.
- Farooq A, Ameen I: Comparison of FNAC vs excision biopsy for suspected tuberculous cervical lymphadenopathy. *Annals of King Edward Medical University* 2016; 9(3).
- Shaha A, Webber C, Marti J: Fine-needle aspiration in the diagnosis of cervical lymphadenopathy. *The American journal of surgery* 1986; 152(4):420-423.
- Lee R, Valaitis J, Kalis O, Sophian A, Schultz E: Lymph node examination by fine needle aspiration in patients with known or suspected malignancy. *Acta cytologica* 1986; 31(5):563-572.
- Dong HY, Harris NL, Preffer FI, Pitman MB: Fine-needle aspiration biopsy in the diagnosis and classification of primary and recurrent lymphoma: a retrospective analysis of the utility of cytomorphology and flow cytometry. *Modern Pathology* 2001; 14(5):472-481.
- Fulciniti F, Vetrani A, Zeppa P, Giordano G, Marino M, ROSA G, Palombini L: Hodgkin's disease: diagnostic accuracy of fine needle aspiration; a report based on 62 consecutive cases. *Cytopathology* 1994; 5(4):226-233.
- Ahmed N, Israr S, Ashraf MS: Comparison of fine needle aspiration cytology (FNAC) and excision biopsy in the diagnosis of cervical lymphadenopathy. *Pak J Surg* 2009; 25:72-75.
- Jha B, Dass A, Nagarkar N, Gupta R, Singhal S: Cervical tuberculous lymphadenopathy: changing clinical pattern and concepts in management. *Postgraduate medical journal* 2001; 77(905):185-187.
- Reddy MP, Moorchung N, Chaudhary A: Clinicopathological profile of pediatric lymphadenopathy. *Indian journal of pediatrics* 2002; 69(12):1047-1051.
- Kardos TF, Vinson JH, Behm FG, Frable WJ, O'dowd GJ: Hodgkin's disease: diagnosis by fine-needle aspiration biopsy: analysis of cytologic criteria from a selected series. *American journal of clinical pathology* 1986; 86(3):286-291.
- Kardos T, Kornstein M, Frable W: Cytology and

- immunocytology of infectious mononucleosis in fine needle aspirates of lymph nodes. *Acta cytologica* 1987; 32(5):722-726.
20. Stanley MW, Horwitz CA, Burton LG, Weisser JA: Negative images of bacilli and mycobacterial infection: A study of fine needle aspiration smears from lymph nodes in patients with aids. *Diagnostic cytopathology* 1990; 6(2):118-121.
 21. Gupta SK, Kumar B, Kaur S: Aspiration cytology of lymph nodes in leprosy. *Int J Lepr* 1981; 49:9-15.
 22. Handa U, Mohan H, Bal A: Role of fine needle aspiration cytology in evaluation of paediatric lymphadenopathy. *Cytopathology* 2003; 14(2):66-69.
 23. Ro J, Lee S, Ayala A: Advantage of Fontana-Masson stain in capsule-deficient cryptococcal infection. *Archives of pathology & laboratory medicine* 1987; 111(1):53-57.
 24. Das D, Pant J, Chachra K, Murthy N, Satyanarayan L, Thankamma T, Kakkar P: Tuberculous lymphadenitis: correlation of cellular components and necrosis in lymph-node aspirate with AFB positivity and bacillary count. *Indian journal of pathology & microbiology* 1990; 33(1):1-10.
 25. Kline TS, Kannan V, Kline IK: Lymphadenopathy and aspiration biopsy cytology. Review of 376 superficial nodes. *Cancer* 1984; 54(6):1076-1081.
 26. Gaber AO, Rice P, Eaton C, Pietrafitta JJ, Spatz E, Deckers PJ: Metastatic malignant disease of unknown origin. *The American journal of surgery* 1983; 145(4): 493-497.
 27. Aggarwal A: One Year Comparative Study Of Diagnostic Efficacy Of Fine Needle Aspiration Cytology Of Cervical And Axillary Lymphadenopathy As Compared To Open Biopsy For Histopathological Examination In Civil Hospital, Belgaum And KLES'S Hospital And Research Centre, Belgaum From July 2003 To June 2004. *RGUHS*; 2006.
 28. Narang R, Pradhan S, Singh R, Chaturvedi S: Place of fine needle aspiration cytology in the diagnosis of lymphadenopathy. *Ind J Tub* 1990; 37(1):29-31.
 29. Prasad R, Garg S, Mukerji P, Agarwal P: Role of fine needle aspiration cytology in the diagnosis of lymphadenopathy. *The Indian journal of chest diseases & allied sciences* 1992; 35(1):27-29.
 30. Ahmad SS, Akhtar S, Akhtar K, Naseem S, Mansoor T: Study of fine needle aspiration cytology in lymphadenopathy with special reference to acid-fast staining in cases of tuberculosis. 2005.
-